

MEETING ABSTRACT

Open Access

Prosthetic repair of left diaphragmatic defect in an elderly patient: a rare case report

M Cimmino*, F Moccia, V Trapani, G Romano, L Fei

From de Senectute: Age and Health Forum
Catanzaro, Italy. 5-7 December 2009

Background

Partial or complete agenesis of the hemidiaphragm is a rare congenital malformation whose embryological basis is unknown. Late presentation is extremely rare and older patients are asymptomatic for a long time without developing ventilator insufficiency, because of the associated lung hypoplasia. Thus, only 7 cases of hemidiaphragmatic agenesis have been reported in adult patients.

Materials and methods

A 71-year-old man came to our Surgical Unit with features of dyspepsia, severe constipation and occasional but increasing episodes of incomplete bowel obstruction accompanied by abdominal distension and pain. Standard chest X-rays showed intestinal gas associated with a reduced diminished pulmonary volume in the left hemithorax (Figure 1A). Contrast medium X-ray of the upper gastrointestinal tract and enema documented the herniation of the stomach and the colon into the thoracic cavity (Figure 1B).

Results

Surgical treatment was carried out through a left subcostal laparotomy extended on the right side. The stomach, transverse colon, splenic flexure, spleen and part of the small bowel were found in the left thoracic cavity. Repair was performed with a 2-mm-tick expanded polytetrafluoroethylene soft tissue patch (Gore-tex®) that was circumferentially anchored tension free to the ribs, intercostals muscles and endothoracic fascia (Figure 1C). Postoperative chest X-rays showed good placement of the new diaphragmatic dome and the fundic air bubble in its correct position (Figure 1D). No early major or

late complications were observed, and no recurrence was found at 34 months' follow-up.

Conclusions

The main questions relating to the management of a large diaphragmatic defect, such as agenesis, concern when and how to operate. We employed an e-PTFE patch, which is currently used for repairing other types of wall defect. This microporous mesh possessed good biocompatibility and produces a low inflammatory and fibrous reaction with a peripheral and interstitial arrangement of collagen fibers that allows the formation of a smooth surface. This surface is able to support a

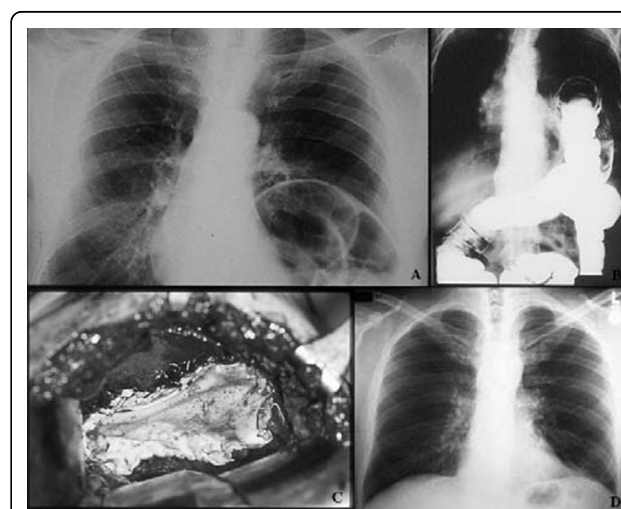


Figure 1 Features of the left diaphragmatic agenesis and positioning of the prosthesis. A) detail of chest x-ray showing the bowel herniation into the left hemithorax; **B)** contrast medium x-ray enema showing herniation of the colon into the left thoracic cavity; **C)** intraoperative picture showing left diaphragmatic agenesis and the e-PTFE Gore-Tex® patch in place; **D)** postoperative standard chest x-ray showing correct position of the new prosthetic diaphragmatic dome.

Department of Clinical and Experimental Medicine and Surgery "F. Magrassi-A. Lanzara". Unit of General Surgery and Digestive Physiopathology, Second University of Naples, 80131 Naples, Italy

continuous layer of mesothelial cells on the peritoneal surface. This mesh seems to be an adequate and satisfactory diaphragmatic substitute, which can easily be used to repair large diaphragmatic defects, ensuring the best anatomical and physiological conditions possible with only a low risk of recurrence.

Published: 19 May 2010

doi:10.1186/1471-2318-10-S1-A4

Cite this article as: Cimmino *et al.*: Prosthetic repair of left diaphragmatic defect in an elderly patient: a rare case report. *BMC Geriatrics* 2010 **10**(Suppl 1):A4.

**Submit your next manuscript to BioMed Central
and take full advantage of:**

- Convenient online submission
- Thorough peer review
- No space constraints or color figure charges
- Immediate publication on acceptance
- Inclusion in PubMed, CAS, Scopus and Google Scholar
- Research which is freely available for redistribution

Submit your manuscript at
www.biomedcentral.com/submit

