

## Familial paragangliomas

CJM Lips<sup>1</sup>, EGWM Lentjes<sup>2</sup>, JWM Höppener<sup>3</sup>, RB van der Luijt<sup>3</sup>, FL Moll<sup>4</sup>

<sup>1</sup>Divisions of Internal Medicine and Endocrinology, <sup>2</sup>Clinical Chemistry and Haematology, <sup>3</sup>Biomedical Genetics and <sup>4</sup>Surgery of the University Medical Center Utrecht, Utrecht, The Netherlands

**Key words:** paragangliomas familial, pheochromocytoma familial, preventive treatment, DNA diagnosis, periodical screening

**Corresponding author:** CJM Lips, Division of Internal Medicine and Endocrinology, University Medical Center Utrecht, Post Office Box 85.500, 3508 GA Utrecht, The Netherlands, phone +31 70 324 04 28, Email: lips05@zonnet.nl

Submitted: 25 October 2006

Accepted: 30 October 2006

This paper has been modified from a paper by the authors, originally published in *Dutch in het Nederlands Tijdschrift voor Oncologie* (the Dutch Journal of Oncology), with permission of that journal.

### Abstract

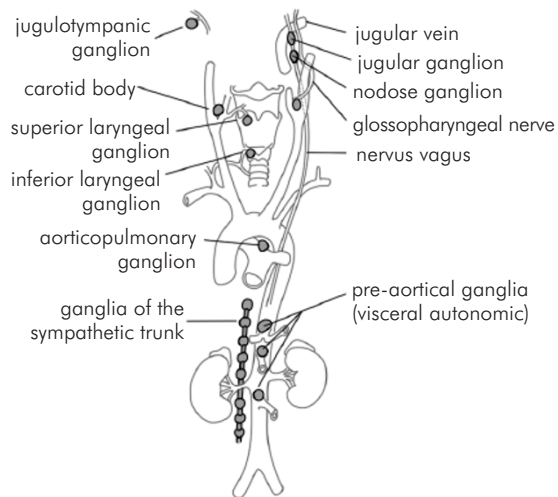
Paragangliomas are rare tumours of the autonomic nervous system and occur in sporadic and hereditary forms. They are usually benign and have a low mortality. However, they cause significant morbidity related to their mass effect. Genetic predisposition can occur within the familial tumour syndromes multiple endocrine neoplasia type 2 (MEN 2), von Hippel-Lindau (VHL) and neurofibromatosis type 1 (NF-1), or be due to mutations in genes specific to the development of paraganglioma only. Compared to sporadic forms, familial paragangliomas tend to present at a younger age and at multiple sites. Tumours should be diagnosed and resected as early as possible, as it has been shown that morbidity is related to tumour size. This article gives an overview of the current literature on the origin of the different forms of paragangliomas, DNA diagnosis, as well as biochemical and radiological screening guidelines.

### Introduction

Paraganglia are groups of neuroendocrine cells scattered throughout the body. They are related to the autonomic nervous system. Mostly they occur in the head (glomus tympanicum and jugular), neck (glomus caroticum and vagal), adrenal medulla, and in the extra-adrenal region in the sympathetic ganglia. During embryogenesis, cells from the neural crest migrate to the sympathetic and parasympathetic nervous system and adrenal medulla. Tumours that develop in cells from paraganglia are called paragangliomas and are classified according to their origin and location (Fig. 1).

Genetic predisposition for paragangliomas exists in relation to the well-known tumour syndromes multiple endocrine neoplasia type 2 (MEN 2), von Hippel-Lindau (VHL) and neurofibromatosis type 1 (NF-1). Besides these syndromes, paragangliomas occur in familial forms without other types of tumours. Compared with sporadic, solitary paragangliomas, familial tumours occur at a younger age and often are multiple in origin.

Paragangliomas that develop in the parasympathetic ganglia mostly have no hormonal activity, whereas paragangliomas derived from sympathetic ganglia can produce catecholamines. Only paragangliomas in the adrenal medulla can produce both noradrenalin and



**Fig. 1.** Paragangliomas classified according to their origin and location. Paragangliomas have their origin in cells derived from the embryological neuroectoderm. There are 4 types of paragangliomas (according to Kleinsasser O. *Arch. Klin. Exp. Ohren, Nasen, Kehlkopfheilkunde*, 1064; 184: 214-25 and Glenner GG, Grimley PM, *Atlas of tumor Pathology* 1974; p. 18)

1. Branchiomeric group: In the region of the embryological branchiomeres (jugulotympanic ganglion, carotid body, laryngeal ganglia, subclavian ganglion, aorticopulmonary ganglion). There is a close relationship with blood vessels.
2. Intravagal group: In the region of the parasympathetic nerves (jugular ganglion, nodose ganglion). They have their origin within the perineurium.
3. Aortosympathetic group: In the region of the sympathetic nerves of the aorta.
4. Visceral autonomic group: in the nervous system of the heart, digestive tract, liver hilus, and bladder.

adrenalin and are called phaeochromocytomas. Extra-adrenal paragangliomas may produce noradrenalin and then stain dark-brown with chromic acid just like phaeochromocytomas (from Greek phaeo).

In a part of the peripheral autonomic nervous system the concentration of oxygen and carbon dioxide in the blood as well as the pressure in the vascular system are measured. This information is passed on to centres in the brain stem, where the frequency of heart rhythm and respiration is regulated. By means of neural stimuli and hormones (such as catecholamines) the blood stream in the arterioles is regulated. Besides this central regulation by the autonomic nervous system and hormones, most tissues are able to contract or relax the muscles in their vessel walls in a process of autoregulation. Peripheral chemoreceptors in the glomus caroticum and glomus aorticum are stimulated if oxygen pressure decreases and carbon dioxide pressure increases. The consequence is peripheral vasoconstriction. Baroreceptors in cells of the aorta and neck arteries regulate blood pressure by stretching of these cells and vasodilatation.

Paragangliomas have their origin especially in neuroendocrine cells that have chemoreceptors. These cells are localized near the great vessels and mostly they develop in the head and neck region. Common characteristics are: they grow slowly and they are benign. The prevalence of paragangliomas is approximately 1 to 30,000. About 10 to 50% of all paragangliomas are familial. Many subjects with genetic predisposition do not have phenotypic expression of the disease. This phenomenon is explained by a mechanism of 'imprinting' (see below). The hereditary predisposition occurs in an equal male-to-female ratio (autosomal dominant inheritance). Expression may occur as early as at age five, whereas in 25% of all carriers expression is found before the age of 25 years. Often, in about 50% of disease gene carriers, there is multicentric involvement. In fact, multicentricity is an indication for hereditary disease in patients with apparently sporadic disease. Sometimes, in about 10% of familial cases of paragangliomas, they occur in the adrenal medulla and produce noradrenalin and adrenalin (phaeochromocytomas). Most frequently, tumours in the glomus caroticum occur (60%) followed by paragangliomas of the inner ear (jugulotympanic paragangliomas). Less than 10% of paragangliomas are malignant.

## Symptomatology

In most patients a local tumour in the neck develops, initially at one side. Mostly the swelling is painless, but it increases slowly in diameter and is usually located under the edge of the jaw. Interruption of nervous tissue may occur by pressure at the base of the skull, e.g. passage of the glossopharyngeal nerve, vagal nerve, and/or accessory in the jugular foramen. Complaints such as choking, defect in speech, tickling cough and pain and weakness in shoulder muscles may occur. Hoarseness and Horner's syndrome frequently occur. In jugulotympanic paragangliomas, tinnitus with the frequency of heart beating, dizziness and blurred vision may occur. Later on, deafness, facial nerve palsy and pain in the inner ear develop.

Sometimes paragangliomas produce amines such as serotonin and/or noradrenalin or their precursors. Production of noradrenalin may evoke hypertension, headache, palpitations and perspiration. These complaints occur in 30% of patients. Paragangliomas in the adrenal glands may produce adrenalin and this occurs in 5% of patients. Infrequently, proteins such as vasoactive intestinal peptide (VIP) or adrenocorticotrophic hormone are produced. Depending on the hormone produced, specific complaints may develop. This occurs only in 2 to 3 % of patients with paragangliomas.

## Diagnosis

Frequently assessment of the diagnosis of paraganglioma by ultrasound is difficult, especially when the primary tumour is located at the base of the skull. The classical applied method of angiography is replaced by magnetic resonance angiography (MRA). In most cases, patients are referred to the out-patient department of throat, nose, and ear diseases because of their complaints of nerve palsy and/or swelling in the neck. This specialist together with the head and neck surgeon will form the team for treatment.

## Natural history

The morbidity of the disease may seriously affect quality of life. In this way swallowing and speech defects and even hemiplegia are caused by damage of the peripheral or central nervous system (cerebrovascular accident, CVA). The final life expectancy is shortened.

## Pathology

Paragangliomas are strongly vascularized. From a histological view, they have a thin capsule and are composed of round polygonal chief cells arranged in compact cell nests ('Zellballen') or trabecular formations. Spindle-like or supporting (sustentacular) cells are situated peripherally. In benign paragangliomas pleomorphism of the nucleus, necrosis, mitosis and some local invasion may be observed. Metastases in lymph nodes, lungs or bones are criteria of malignancy. This occurs in less than 10%. The neuroendocrine character can be demonstrated by immunohistochemical methods. Neuron-specific enolase (NSE), synaptophysin and chromogranin may be demonstrated in chief cells.

By means of electron microscopy ultrastructural neurosecretory granules are demonstrable. They may contain biogenic amines such as noradrenalin, adrenalin, serotonin or their precursors (dopamine and 5-hydroxytryptophane, respectively). Unfortunately, at this moment it is impossible to predict the prognosis on the basis of histological grounds. Criteria such as mitoses, nuclear pleomorphism or invasiveness appear to be unreliable. In the near future, molecular biochemical examination (expression profiles) may provide more insight into additional mutations and 'multistep carcinogenesis'.

## Molecular genetics

### Hereditary predisposition

If bilateral paraganglioma are assessed, in most cases a hereditary disease is present. The predisposition

is passed from one of the parents to her/his child or a *de novo* mutation in the germ line of the patient her/himself has occurred.

The genetic defect of paragangliomas is an inactivating mutation in one of the paraganglioma genes, the so-called **PGL genes**. These mutations may occur somatically or be present in the germ line. Somatic, inactivating mutations result in sporadic, mostly solitary tumours. If a germ line mutation is present, a hereditary form will occur, mostly multiple and at a young age.

## Genes responsible for the development of paraganglioma

### Molecular biology of respiration

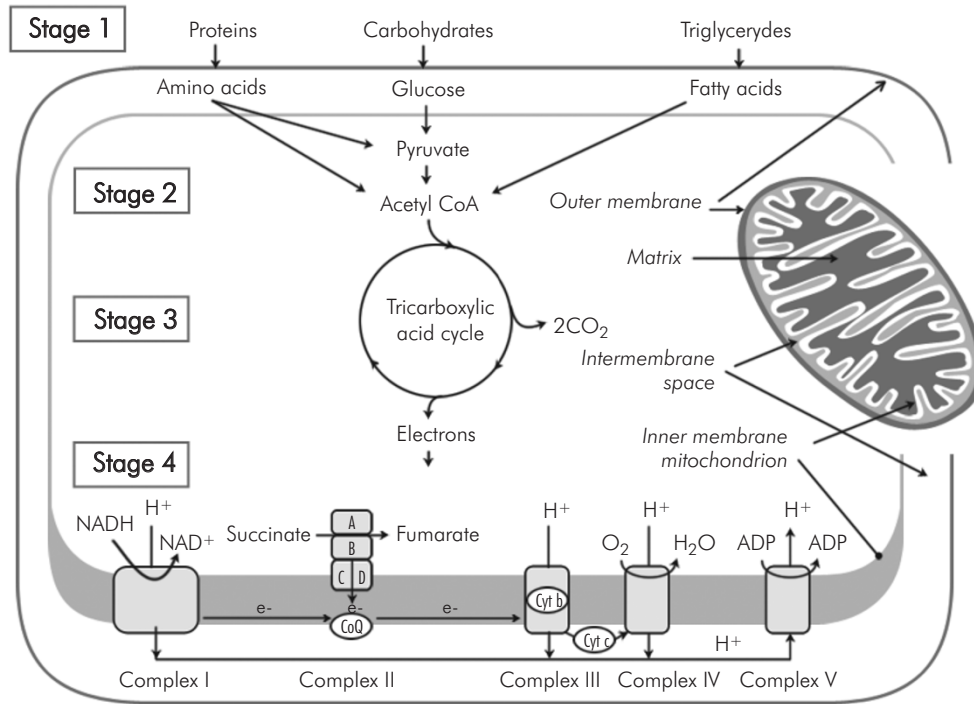
In primates adenosine triphosphate (ATP) is the source of energy for most biological processes. Energy necessary for synthesis of ATP is obtained by oxidation of nutrients. Two processes are involved in transformation of energy: citric acid or tricarboxylic acid (TCA) cycle and oxidative phosphorylation (respiration chain). Both processes occur in the mitochondria (Fig. 2).

In the process of oxidative phosphorylation 5 enzyme complexes (I-V) are involved, which are anchored in the inner membrane. Three genes encoding the proteins B, C and D of complex II are involved in the development of paragangliomas. All four different proteins (A, B, C and D) of complex II are encoded by the nuclear genome. The proteins C and D are anchored in the inner mitochondrial membrane. The proteins A and B have a catalytic function (enzymes).

### Origin of paragangliomas

Mutations in DNA of genes encoding enzymes called succinate dehydrogenase (SDH) are associated with development of paragangliomas. The derived proteins SDH-B, -C and -D are enzymes that belong to complex II of the respiratory chain of mitochondria (Fig. 2) [1].

Chemoreceptors detect a shortage of oxygen. Hypoxia can be compensated by the lungs by breathing faster and deeper. In the cells of the paraganglia, hypoxia will promote expression of factors that stimulate angiogenesis. It is generally assumed that "vasoactive endothelial growth factor" (VEGF) and "reactive oxygen species" (ROS) are responsible directly for cell division and tumour development. Thus paragangliomas will occur more frequently in smokers and people living at a high altitude (in Tibet, in the Andes mountains) and in patients with chronic pulmonary diseases [2].



**Fig. 2.** Cells obtain their energy from their environment by oxidation of carbohydrates, proteins and triglycerides to CO<sub>2</sub> and H<sub>2</sub>O. The energy from these macronutrients is transformed into ATP in 4 different stages  
 Stage 1 – hydrolysis of macromolecules into monosaccharides, fatty acids, amino acids  
 Stage 2 – oxidation into Acetyl Co A  
 Stage 3 – Acetyl Co A oxidation into Tricarboxylic acid (TCA) cycle → CO<sub>2</sub>  
 Stage 4 – reduction NAD → NADH, FAD → FADH<sub>2</sub>, phosphorylation ATP → H<sub>2</sub>O and ATP

If in a cell of a paraganglioma a mutation is present in one of the SDH genes, insufficient ATP will be available in relation to the need for energy. Only a weak signal will be sent to the centres in the medulla oblongata to the heart and lungs. If in a paraganglion cell a low

concentration of SDH protein is present, this cell will tend to divide. SDH proteins take care of differentiation and stabilization, and inhibit cell division. For that reason SDH genes are called tumour-suppressor genes. An overview of the PGL genes is given in Table 1.

**Table 1.** Overview of the PGL and SDH genes

PGL gene	encoded Protein	chromosomal location	characteristics
PGL1	SDHD	11q23	maternal imprinting
PGL4	SDHB	1p35-36	autosomal dominant inheritance
PGL3	SDHC	1q21	autosomal dominant inheritance
PGL2	–	11q13	maternal imprinting*
	SDHA	5p15	optic atrophy, myopathy, ataxia, Leigh syndrome, recessive no paragangliomas

\* The PGL2 gene has not yet been identified.

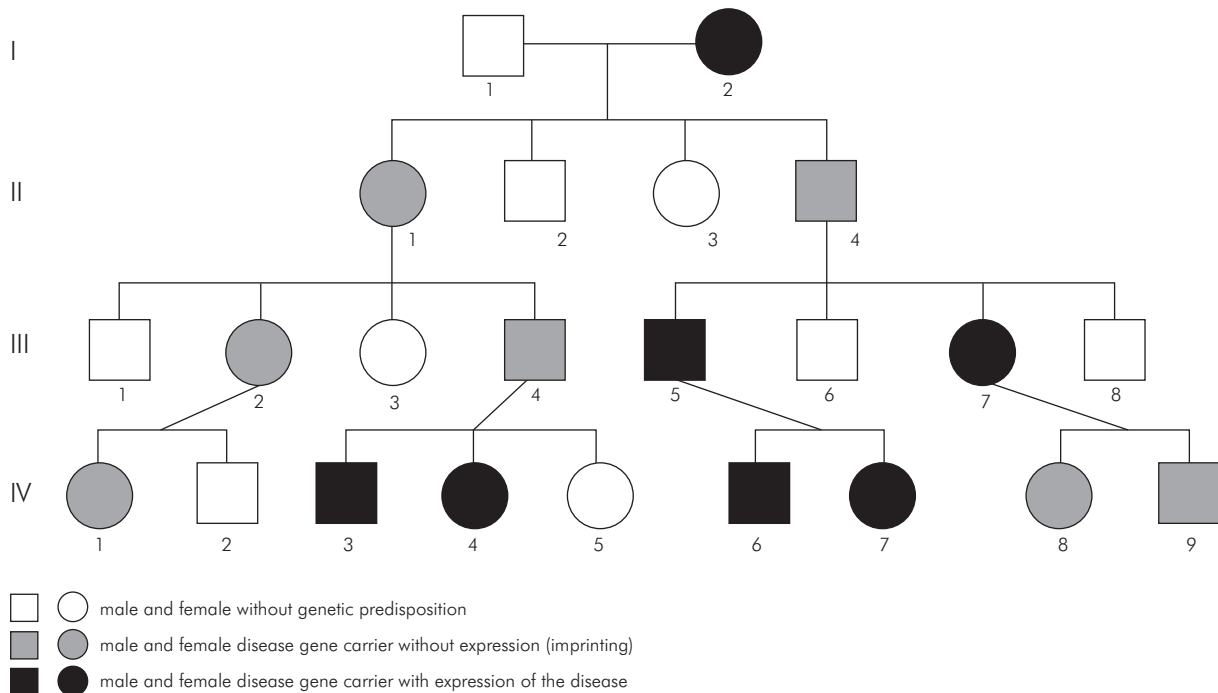
## The PGL genes and complex II

### 1. SDHD gene 1 (PGL1)

This is the most important paraganglioma gene. It is located on the long arm of chromosome 11 (11q23) [3]. The gene encodes an anchor protein, SDHD, that belongs to the succinate dehydrogenase mitochondrial complex II. This enzyme is involved in cell metabolism and energy supply. Expression of this gene is subject to genomic imprinting.

### 2. SDHB gene (PGL4)

The SDHB gene is located on chromosome 1p35-p36. It encodes the catalytic subunit B of the SDH complex. The SDHB protein is involved in head and neck



**Fig. 3.** Imaginary example of a family with hereditary paragangliomas and genomic imprinting. The pedigree has four generations (I-IV). Expression of the disease skips one or two generations. In these generations, the genetic predisposition is present. In the first generation (I) the mother (I 2) is a carrier of the paraganglioma disease gene and has expression of the disease. Her daughter (II 1) inherited the mutated paraganglioma gene, but will not develop paragangliomas. She will transfer the mutated paraganglioma gene to two of her children (daughter III 2 and son III 4). These children will not develop the disease, but pass the predisposition to the next generation. The granddaughter of (II 1) IV 1 has the predisposition but no expression, whereas the grandson IV 3 and granddaughter IV 4 have both the predisposition and expression of the disease. The son (II 4) of I 2 has also inherited the disease gene from his mother, but will not have symptoms. His son (III 5) is a paraganglioma carrier and will have complaints just the same as his sister III 7. His children (IV 6 and 7) have predisposition for paragangliomas and will have the disease. The son and daughter (IV 8 and 9) of III 7 do inherit the mutated paraganglioma gene from their mother, but will not have symptoms.

paragangliomas and in paragangliomas of the adrenal medulla [4]. In contrast to the SDHD gene, no imprinting is present. Mutations in the SDHB gene give a higher risk for malignant, especially extra-adrenal abdominal, paragangliomas than SDHD mutations do [5-7].

### 3. SDHC gene (PGL3)

This gene is located on chromosome 1q21 and encodes the second anchor protein (C) of the mitochondrial complex II. Also mutations in this gene may cause hereditary paragangliomas; however, these mutations occur less frequently than SDHD mutations [8].

### 4. SDHA gene (this is not a PGL gene)

This gene encodes the catalytic subunit A of mitochondrial complex II. Mutations in this gene cause a disease involving a combination of atrophy of the optical nerve, myopathy and ataxia, although without paragangliomas. This syndrome is called Leigh's syndrome. The gene is located on chromosome 5p15.

## The PGL2 gene

The PGL2 gene has not yet been identified. This putative gene is located on chromosome 11 in the region of 11q13 [9]. In this region no other genes involved in the SDH mitochondrial complex II are found.

### Transmission of the disease

SDHB and SDHC families show autosomal dominant inheritance of the disease, whereas SDHD and PGL2 families only have an autosomal dominant pattern of inheritance if the disease gene is transmitted by the father (see paragraph below).

### Inheritance of the expression of paragangliomas. The concept of genomic imprinting

If a child inherits a mutated paraganglioma gene from one of its parents, it becomes a disease-gene

**Table 2.** Guidelines for periodical examination

---

**Which disease gene carrier has to be investigated periodically and when?**

- Carriers of a hereditary mutation of the PGL1 or PGL2 gene only if they have inherited the disease gene from their father (the paternal PGL disease gene) (thus in SDHD and PGL-2)
- all carriers of a PGL 3 or PGL 4 disease gene, irrespective of the gender of the genetically affected parent

Preferably, DNA analysis should be performed at an age between 5 and 10 years. This is the age at which periodical screening should have been started.

---

**How frequently does periodical examination have to be performed?**

In cases where tumours grow slowly and there are no symptoms or signs of expression of the disease, every three years:

- 24-hour urine on metabolites of noradrenaline and adrenaline
- ultrasound of the neck
- duplex examination of blood vessels in the neck
- MRI from the age of 10 onwards

If there are symptoms or signs of expression of the disease:

Consider surgical removal and in any case every year:

- 24-hour urine on metabolites of noradrenaline and adrenaline
  - ultrasound of the neck
  - duplex examination of blood vessels in the neck
  - MRI from the age of 10 onwards
- 

carrier. Yet it does not always have to experience complaints in the course of its life. Whether the child will have expression of the disease depends on the gender of the parent that passed on the genetic predisposition. If a father has the hereditary predisposition, half of his children irrespectively of sex will have both predisposition and expression of the disease. If the mother has the predisposition to the disease, this predisposition is transmitted, but expression does not occur. This phenomenon is called "Maternal imprinting": the gene that causes the disease is switched off (suppressed) if it is transmitted via the egg cell. In contrast, the same gene is fully active if it is transmitted via the spermatozoon. In "paternal imprinting" exactly the opposite occurs (e.g. in pseudohypoparathyroidism).

Exclusive transmission of the disease via the father may be explained by a hereditary mutation of the SDHD gene from the father combined with imprinting of the homologous allele from the mother, together with the loss of 11p15, 5. This may occur by loss of the whole maternal chromosome 11 [10].

## Periodical examination

Treatment of small tumours involves less risk than larger ones. For that reason, periodical examination and early treatment are recommended. Knowledge about the mutation and expression of the disease within the family is desired. The protocol for periodic clinical examination depends on these data. The guidelines for examination, the individuals to be examined, and the frequency and

methods of investigation are given in Table 2. In all carriers of a mutation life-long follow-up is indicated.

## DNA diagnosis

In children from well-known families identified with paragangliomas, DNA analysis should be performed preferably at an age between 5 and 10 years. This is the age at which periodical examination should be started [11].

If in patients with apparently sporadic tumours the family history raises suspicion about the occurrence of paraganglioma-associated tumours, DNA analysis is indicated. If a phaeochromocytoma or paraganglioma is revealed at a young age or if multiple or bilateral tumours are encountered whereas the family history is negative, DNA analysis may be performed [12-14].

## Visualisation of tumours

### Radiological examination

Routinely periodical examination using ionising radiation has to be avoided.

Ultrasound-Doppler or duplex examination may clarify how blood supply and the direction of growth of a paraganglioma occur, and thus whether a paraganglioma finds its origin in the glomus caroticum, the nervus vagus or in the ganglion jugulotympanicum.

MR angiography enables mapping of blood supply. Digital subtraction angiography may reveal particular details.



## Nuclear examination

Metaiodobenzylguanidine (MIBG) and somatostatin-receptor scintigraphy enable the localization of additional lesions or metastases. If positive, there may be consequences for treatment. Overproduction of noradrenalin occurs in 37.5% and phaeochromocytomas occur in 20% [15]. Overproduction of serotonin occurs in only 3%; however, the precursor 5-hydroxytryptophane (5 (OH) HTP) is over-produced much more frequently.

Paragangliomas take up precursors of biogenic amines and this capacity enables localisation of small paragangliomas. Positron emission tomography (PET) using  $^{11}\text{C}$ -5-hydroxytryptophane (5HTP)-PET and/or 6- $^{18}\text{F}$ -fluorodopamine-PET may be applied [16, 17].

## Surgical treatment

Early detection and treatment of tumours result in the smallest risk for morbidity from surgery. In larger paragangliomas, embolization of the main arterial blood supply preoperatively may reduce the risk of haemorrhage or other complications during surgery. This procedure belongs in experienced hands, because in e.g. glomus caroticum tumours there is a considerable risk of an embolism to the brain. Preferably, suspected lymph nodes on the side of the paraganglioma have to be removed during surgery, even if the risk is small that metastases are present [18-20]. In the case of large tumours, it will be impossible to treat curatively. Conservative surgical treatment may leave the large vessels intact so that morbidity is limited. Preferably, surgery is performed by a team with knowledge and experience in the head and neck region (throat, nose, and ear physician, head and neck surgeon, and a vascular surgeon) experienced with vascular reconstruction.

Many paragangliomas are able to produce catecholamines, especially dopamine and noradrenaline, and if localised in the adrenal glands also adrenaline. Preoperative treatment with alpha- and beta-receptor blocking agents may be useful.

## If surgical treatment is not possible anymore

If intracranial extension is present and removal of the paraganglioma is not possible without serious deletion of surrounding structures (nerves and blood vessels) or if metastases are present at a distance, treatment with other methods may be discussed. Treatment with somatostatin analogues appears to have little effect on the diameter of a paraganglioma, but may give subjective improvement of symptoms in malignant paragangliomas.

Therapy with radioactive octreotide or MIBG may be effective. Also, in a selected group of patients, a favourable result may be expected from external beam radiation. Stereotactic radiosurgery (gamma knife surgery) may provide relief of symptoms. In the case of malignant paragangliomas, one may expect partial remission from chemotherapy with cyclophosphamide, vincristine, dacarbazine (CVD), with or without doxorubicin [21, 22].

## Practical guidelines for clinicians

- especially children of fathers with a SDHD mutation have to be investigated periodically
- early diagnosis is indicated, because morbidity is related to the diameter of the tumour
- if possible, resection of a paraganglioma has to be performed at an early stage
- preferably, the surgical procedure should be performed by surgeons with experience in the head and neck region and in techniques of vascular reconstruction
- DNA analysis of children from families with a known SDH mutation has to be performed before the age of 5 years

## References

1. DiMauro S, Schon EA. Mitochondrial respiratory-chain diseases. *N Engl J Med* 2003; 348: 2656-2668.
2. Rodriguez-Cuevas S, Lopez-Garza J, Labastida-Almendaro S. Carotid body tumors in inhabitants of altitudes higher than 2000 meters above sea level. *Head Neck* 1998; 20: 374-378.
3. Baysal BE, Ferrell RE, Willett-Brozick JE, Lawrence EC, Myssiorek D, Bosch A, van der Mey A, Taschner PE, Rubinstein WS, Myers EN, Richard CW 3rd, Cornelisse CJ, Devilee P, Devlin B. Mutations in SDHD, a mitochondrial complex II gene, in hereditary paraganglioma. *Science* 2000; 287: 848-851.
4. Astuti D, Latif F, Dallol A, Dahia PL, Douglas F, George E, Skoldberg F, Husebye ES, Eng C, Maher ER. Gene mutations in the succinate dehydrogenase subunit SDHB cause susceptibility to familial pheochromocytoma and to familial paraganglioma. *Am J Hum Genet* 2001; 69: 49-54.
5. Gimenez-Roqueplo AP, Favier J, Rustin P, Rieubland C, Crespin M, Nau V, Khau Van Kien P, Corvol P, Plouin PF, Jeunemaitre X; COMETE Network. Mutations in the SDHB gene are associated with extra-adrenal and/or malignant phaeochromocytomas. *Cancer Res* 2003; 63: 5615-5621.
6. Young AL, Baysal BE, Deb A, Young WF Jr. Familial malignant catecholamine-secreting paraganglioma with prolonged survival associated with mutation in the succinate dehydrogenase B gene. *J Clin Endocrinol Metab* 2002; 87: 4101-4105.
7. Maier-Woelfle M, Brandle M, Komminoth P, Saremaslani P, Schmid S, Locher T, Heitz PU, Krull I, Galeazzi RL, Schmid C, Perren A. A novel succinate dehydrogenase subunit B gene mutation, H132P, causes familial malignant sympathetic extraadrenal paragangliomas. *J Clin Endocrinol Metab* 2004; 89: 362-367.
8. Niemann S, Muller U. Mutations in SDHC cause autosomal dominant paraganglioma, type 3. *Nat Genet* 2000; 26: 268-270.

9. Mariman EC, van Beersum SE, Cremers CW, van Baars FM, Ropers HH. Analysis of a second family with hereditary non-chromaffin paragangliomas locates the underlying gene at the proximal region of chromosome 11q. *Hum Genet* 1993; 91: 357-361.
10. Hensen EF, Jordanova ES, van Minderhout IJ, Hogendoorn PC, Taschner PE, van der Mey AG, Devilee P, Cornelisse CJ. Somatic loss of maternal chromosome 11 causes parent-of-origin-dependent inheritance in SDHD-linked paraganglioma and pheochromocytoma families. *Oncogene* 2004; 23: 4076-4083.
11. Dundee P, Clancy B, Wagstaff S, Briggs R. Paraganglioma: the role of genetic counselling and radiological screening. *J Clin Neurosci* 2005; 12: 464-466.
12. Astuti D, Hart-Holden N, Latif F, Laloo F, Black GC, Lim C, Moran A, Grossman AB, Hodgson SV, Freemont A, Ramsden R, Eng C, Evans DG, Maher ER. Genetic analysis of mitochondrial complex II subunits SDHD, SDHB and SDHC in paraganglioma and pheochromocytoma susceptibility. *Clin Endocrinol (Oxf)* 2003; 59: 728-733.
13. Gimm O, Armanios M, Dziema H, Neumann HP, Eng C. Somatic and occult germ-line mutations in SDHD, a mitochondrial complex II gene, in nonfamilial pheochromocytoma. *Cancer Res* 2000; 60: 6822-6825.
14. Dannenberg H, van Nederveen FH, Abbou M, Verhofstad AA, Komminoth P, de Krijger RR, Dinjens WN. Clinical characteristics of pheochromocytoma patients with germline mutations in SDHD. *J Clin Oncol* 2005; 23: 1894-1901.
15. van Houtum WH, Corssmit EP, Douwes Dekker PB, Jansen JC, van der Mey AG, Brocker-Vriends AH, Taschner PE, Losekoot M, Frolich M, Stokkel MP, Cornelisse CJ, Romijn JA. Increased prevalence of catecholamine excess and pheochromocytomas in a well-defined Dutch population with SDHD-linked head and neck paragangliomas. *J Endocrinol* 2005; 152: 87-94.
16. Orlefors H, Sundin A, Garske U, Juhlin C, Oberg K, Skogseid B, Langstrom B, Bergstrom M, Eriksson B. Whole-body (11)C-5-hydroxytryptophan positron emission tomography as a universal imaging technique for neuroendocrine tumors: comparison with somatostatin receptor scintigraphy and computed tomography. *J Clin Endocrinol Metab* 2005; 90: 3392-3400.
17. Eriksson B, Orlefors H, Oberg K, Sundin A, Bergstrom M, Langstrom B. Developments in PET for the detection of endocrine tumours. *Best Pract Res Clin Endocrinol Metab* 2005; 19: 311-324.
18. Patetsios P, Gable DR, Garrett WV, Lamont JP, Kuhn JA, Shutze WP, Kourlis H, Grimsley B, Pearl GJ, Smith BL, Talkington CM, Thompson JE. Management of carotid body paragangliomas and review of a 30-year experience. *Ann Vasc Surg* 2002; 16: 331-338.
19. Favier J, Briere JJ, Strompf L, Amar L, Filali M, Jeunemaitre X, Rustin P, Gimenez-Roqueplo AP. Hereditary paraganglioma/pheochromocytoma and inherited succinate dehydrogenase deficiency. For the PGL.NET Network. *Horm Res* 2005; 63: 171-179.
20. Gimenez-Roqueplo AP, Favier J, Rustin P, Rieubland C, Kerlan V, Plouin PF, Rotig A, Jeunemaitre X. Functional consequences of a SDHB gene mutation in an apparently sporadic pheochromocytoma. *J Clin Endocrinol Metab* 2002; 87: 4771-4774.
21. Patel SR, Winchester DJ, Benjamins RS. A 15-year experience with chemotherapy of patients with paraganglioma. *Cancer* 1995; 76: 1476-1480.
22. Averbuch SD, Steakley CS, Young RC, Gelmann EP, Goldstein DS, Stull R, Keiser HR. Malignant pheochromocytoma: effective treatment with a combination of cyclophosphamide, vincristine, and dacarbazine. *Ann Intern Med* 1988; 109: 267-273.