



Case report

Primitive neuroectodermal tumor of the kidney in an adult: a case report

Adrian Businger¹, Andreas Zettl², Stefan Sonnet³, Robin Ruszat⁴
and Markus von Flüe^{1*}

Addresses: ¹Department of Surgery, St. Claraspital, Kleinriehenstrasse 30, CH-4016 Basel, Switzerland, ²Pathology Viollier, Jacob Burckhardt-Strasse 86, Postfach, CH-4002 Basel, Switzerland, ³Department of Radiology, St. Claraspital, Kleinriehenstrasse 30, CH-4016 Basel, Switzerland and ⁴Urology Unit, St. Claraspital, Kleinriehenstrasse 30, CH-4016 Basel, Switzerland

Email: AB - adrian.businger@claraspital.ch; AZ - andreas.zettl@viollier.ch; SS - stefan.sonnet@claraspital.ch; RR - robin.ruszat@claraspital.ch; MVF* - markus.vonfluee@claraspital.ch

* Corresponding author

Received: 23 March 2009 Accepted: 1 April 2009 Published: 5 June 2009

Cases Journal 2009, **2**:6791 doi: 10.4076/1757-1626-2-6791

This article is available from: <http://casesjournal.com/casesjournal/article/view/6791>

© 2009 Businger et al; licensee Cases Network Ltd.

This is an Open Access article distributed under the terms of the Creative Commons Attribution License (<http://creativecommons.org/licenses/by/3.0>), which permits unrestricted use, distribution, and reproduction in any medium, provided the original work is properly cited.

Abstract

Introduction: Primitive neuroectodermal tumors (PNETs) occur predominantly in childhood preferentially in the soft tissues of the lower extremity and the paraspinal region. We present here a rare case of a PNET of the kidney in an adult.

Case presentation: A tumor adjacent to the right kidney was detected by ultrasound coincidentally at a routine check-up in a 46-year-old woman with irritable bowel syndrome in her medical history. The patient had no clinical signs. Contrast-enhanced computerized tomography scan of the abdomen demonstrated a highly vascularized renal tumor. A retroperitonelectomy with en-bloc resection of the kidney was performed, and histopathological work-up showed a primitive neuroectodermal tumor of the kidney with the characteristic translocation t(11;22)(q24;q12).

Conclusion: This tumor entity must be accurately distinguished from other renal neoplasms because of the prognostic and therapeutic impact.

Introduction

Small round cell tumors of the kidney encompass a broad range of neoplasms including lymphoma, clear cell sarcoma of the kidney, neuroblastoma, monophasic Wilms' tumor, carcinoid, desmoplastic small round cell tumor, synovial sarcoma and extraskeletal Ewing sarcoma/primitive neuroectodermal tumor (ES/PNET) with overlapping morphologic features but different therapeutic

regimes. The latter is a rare neoplasm with early regional and distant (lungs, liver, bone) metastasis [1]. The prognosis is poor with a 5-year disease-free survival rate of about 50% despite multimodal therapy [2]. The diagnosis and differential diagnosis is based on immunohistochemical phenotypes and molecular studies [3]. In 1994, Mor described the first case of a ES/PNET in the kidney [4].

Here, we report another patient with a primary renal ES/PNET.

Case presentation

During medical examination on the occasion of a routine sonography, an asymptomatic tumor directly near the right kidney and with possible renal origin was detected in a 46-year-old Caucasian woman and Swiss citizen with a history of former smoking with 10 pack-years, irritable bowel syndrome with recurring mild abdominal pain, and a past fibroadenoma excision in the right breast five years ago. The patient complained neither of micturition symptoms nor of fever or febleness. She had no history of weight loss, but she suffered from night sweats for one month. She had no medication history, and physical findings and laboratory tests were normal. Contrast-enhanced CT scan of the abdomen showed a highly vascularized, well-defined renal tumor with dimensions of 45 × 65 × 102 mm. The mass extended towards the renal pelvis and the right kidney itself was therefore laterally displaced. There was an apparent infiltration of the renal parenchyma or the urinary tract collection system (Figure 1). The 3D-reconstruction of abdominal CT angiography at arterial phase showed an extensive tumor vascularization with feeding and draining vessels and arteriovenous shunt formation (Figure 2). Abdominal MRI confirmed the tumor with an extensive vascularization. We performed an open retroperitonelectomy with removal of the right kidney en-bloc with a caudo-cranial-mobilization of the tumor and several ligations of the ovarian vein, the duplicated renal artery, and the likewise duplicated renal

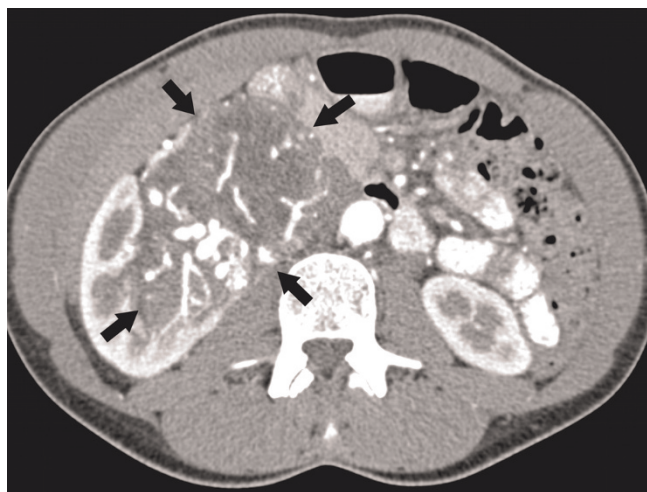

Figure 1. Contrast-enhanced CT scan of the abdomen shows a well-defined, highly vascularized renal tumor. The mass extends towards the renal pelvis and the right kidney is laterally displaced. Tumor borders are indicated by arrows.

vein. The tumor showed extremely dilated veins on its surface.

Macroscopically, the nephrectomy specimen measured 15 × 12 × 6 cm and weighted 468 g. Almost the whole kidney was infiltrated by a tan to grey, soft tumor mass with multiple foci of necrosis. The tumor had spread to the renal hilus with encasement of the renal artery and vein; the perirenal fatty tissue was free of tumor. The resection margins were free of tumor.

Histological examination revealed a uniform population of tumor cells with round to oval nuclei, very small nucleoli, smoky chromatin, slightly irregular nuclear membranes and small, intensely PAS+ cytoplasm (Figure 2c). Numerous signs of mitosis and scattered apoptosis as well as geographic zones of necrosis were encountered (Figures 3-5).

Immunohistochemical stainings were performed using the automated Bond-maX system (Vision Biosystems, Novocastra). The tumor cells showed strong positivity for CD99 (1:200, Novocastra) (Figure 6), vimentin (1:1000, Dako) and NSE (neuron specific enolase, 1:200, Novocastra).

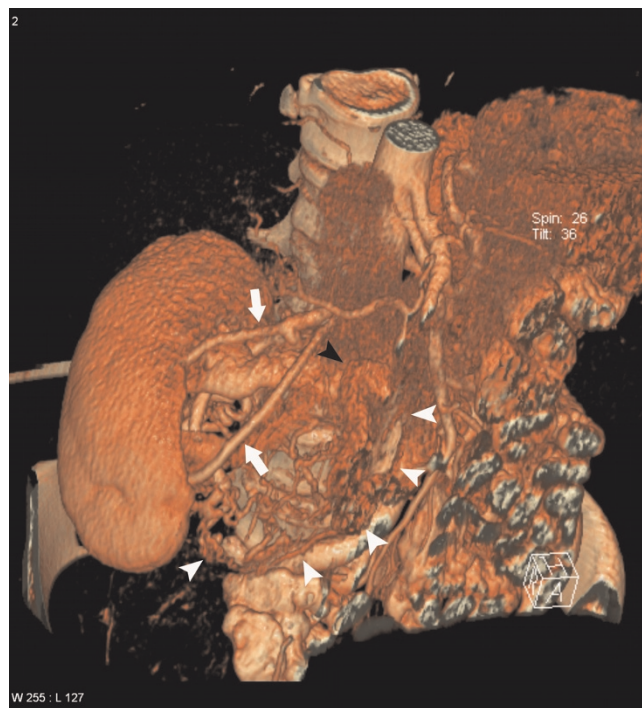

Figure 2. CT angiography of the abdomen at arterial phase shows an extensive tumor vascularization with feeding and draining vessels and arteriovenous shunt formation: Feeding renal arteries (white arrows). Main draining vein (black arrowhead). Pathological vessels (white arrowheads).

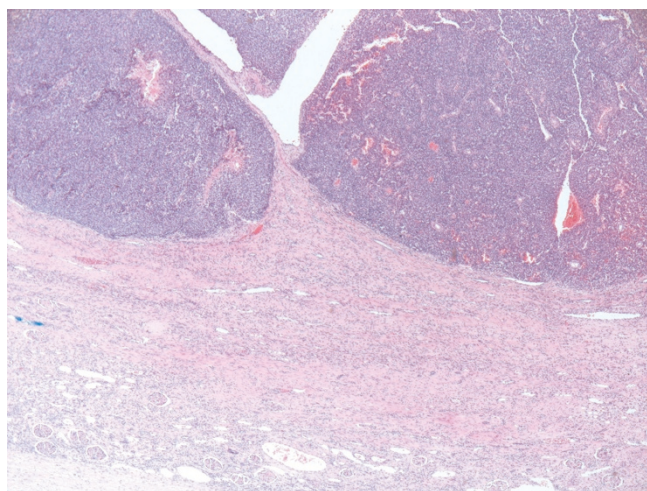


Figure 3. At scanning magnification (HE stain, ×40), a highly cellular neoplasm is seen infiltrating the kidney.

Immunostainings for cytokeratin AE1/3 [(1:800, Dako), EMA (1:50, Dako), S100 (1:24000, Dako), LCA (1:800, DAKO)], CD117 (1:50, Dako), and CD34 (1:400, Dako) were negative.

In molecular studies (performed by L. Guillou, University of Lausanne, Switzerland), the tumor showed the characteristic translocation t(11;22)(q24;q12) with a EWSR1/FLI1 fusion transcript. A diagnosis of primary ES/PNET of the kidney was rendered [4].

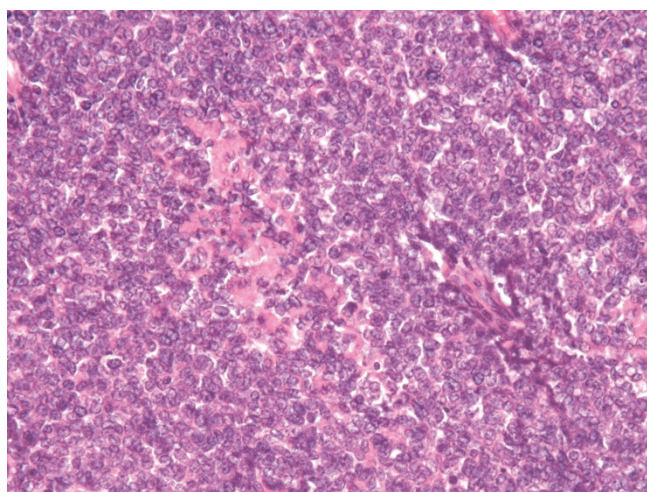


Figure 4. At higher magnification (×200), the neoplasm appears to be composed of tumor cells with round to oval nuclei, very small nucleoli, smoky chromatin, slightly irregular nuclear membranes.

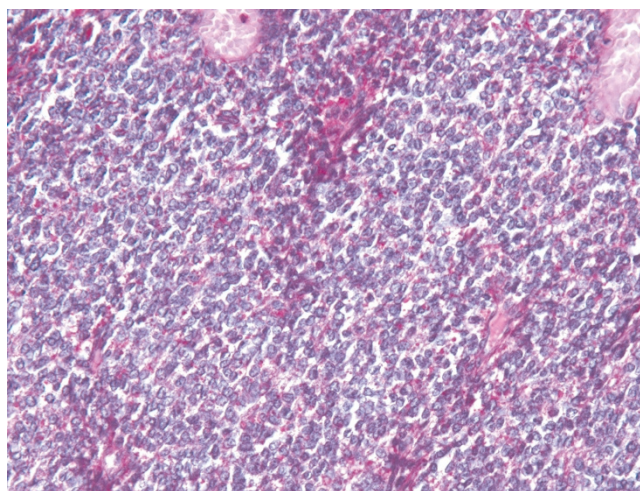


Figure 5. At higher magnification (×200), the neoplasm appears to be composed of tumor cells with round to oval nuclei, very small nucleoli, smoky chromatin, slightly irregular nuclear membranes and small, intensely PAS+ cytoplasm.

Postoperatively, the patient recovered well and was discharged from the hospital after 14 days. She was treated according to the EURO/E.W.I.N.G. 99-protocol with one course of VAI (vincristine, actinomycin D and ifosfamide), followed by seven chemotherapy courses according to the FVAC schema (vincristine, actinomycin and Endoxan).

Discussion

ES/PNETs of the kidney are extremely rare disease entities [5] and are morphologically and immunophenotypically indistinct from extrarenal ES/PNET [6]. They

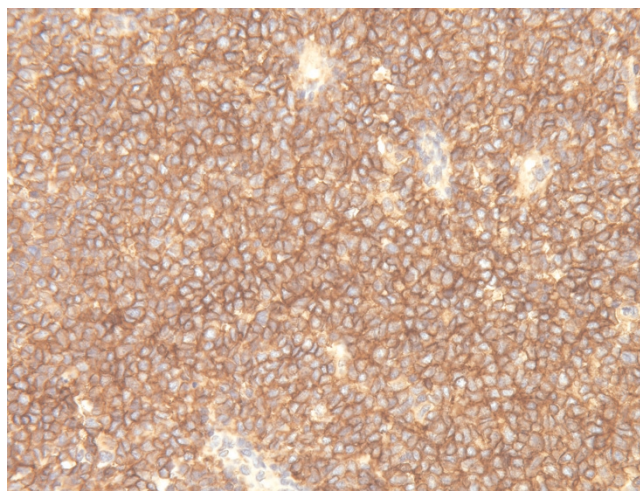


Figure 6. The tumor cells strongly express CD99 (×200).

show the same gene fusions [7] and have a similar poor outcome. In 1994, Mor described the first case of a renal ES/PNET [4]. Subsequently, several case reports and small series of renal PNET were reported in the literature [6,8-10]. Reportedly, renal ES/PNET usually arises in young adults and shows a slight male predominance. Clinically, the tumors usually behave aggressively with frequent metastasis and tumor-related death. In our case, the tumor was asymptomatic and only detected coincidentally. Histologically, several other small round cell tumors enter into the differential diagnosis of renal ES/PNET. Morphological, immunophenotypical and molecular studies are needed to exclude a blastema-predominant Wilms' tumor (which may show areas of stromal or epithelial differentiation, is rarely CD99 positive but frequently shows WT1 expression), metastatic neuroblastoma and clear cell sarcoma (which usually arise in younger patients), synovial sarcoma (which commonly expresses cytokeratin or EMA and shows the characteristic t(X;18)), and small cell carcinoma and lymphoma (which show completely different immunophenotypes). Nonuniform nomenclature of the entity "renal ES/PNET" may have led to underreporting of this entity [11].

Conclusion

Renal ES/PNET is rare. Differentiation of small round cell tumors of the kidney may be challenging, and asymptomatic lesions in this location are often detected only by chance. In spite of surgical removal and the application of chemotherapy in this chemosensitive tumor with the same nosologic form as Ewing's sarcoma [12], disease-free survival is poor.

List of abbreviations

NSE, neuron specific enolase; CT, computed tomography; MRI, magnetic resonance imaging; ES, Ewing sarcoma; PNET, primitive neuroectodermal tumor.

Consent

Written informed consent was obtained from the patient for publication of this case report and accompanying images. A copy of the written consent is available for review by the Editor-in-Chief of this journal.

Competing interests

The authors declare that they have no competing interests.

Authors' contributions

AB, SS, RR and MvF treated the patient and were responsible for writing the paper and looking up the background references. AZ was the pathologist in charge. MvF was responsible for over all coordination and final proofreading of the manuscript. All the above-mentioned authors read and approved the final manuscript.

Acknowledgments

The authors acknowledge Martin Buess, oncologist, St. Claraspital, Basel, Switzerland for his valuable intellectual input, Robert Lemoine, MD, Pathology Viollier Weintraub SA, Geneva, Switzerland for his initial diagnosis, and Louis Guillou, MD, Department of Pathology, Centre Hospitalier Universitaire Vaudois CHUV, Lausanne, Switzerland for his consultation diagnosis and the molecular characterization of the tumor.

References

1. Marina NM, Etcubanas E, Parham DM, Bowman LC, Green A: **Peripheral primitive neuroectodermal tumor (peripheral neuroepithelioma) in children. A review of the St. Jude experience and controversies in diagnosis and management.** *Cancer* 1989, **64**:1952-1960.
2. Kushner BH, Hajdu SI, Gulati SC, Erlandson RA, Exelby PR, Lieberman PH: **Extracranial primitive neuroectodermal tumors. The Memorial Sloan-Kettering Cancer Center experience.** *Cancer* 1991, **67**:1825-1829.
3. Friedrichs N, Vorreuther R, Poremba C, Schafer KL, Böcking A, Buettner R, Zhou H: **Primitive neuroectodermal tumor (PNET) in the differential diagnosis of malignant kidney tumors.** *Pathol Res Pract* 2002, **198**:563-569.
4. Mor Y, Nass D, Raviv G, Neumann Y, Nativ O, Goldwasser B: **Malignant peripheral primitive neuroectodermal tumor (PNET) of the kidney. A clinicopathologic and immunohistochemical analysis of 11 cases.** *Am J Surg Pathol* 2002, **26**:320-327.
5. Antoneli CB, Costa CM, de Camargo B, Sredni ST, Alfer W Jr, Chojniak R: **Primitive neuroectodermal tumor (PNET)/extraosseous Ewing sarcoma of the kidney.** *Med Pediatr Oncol* 1998, **30**:303-307.
6. Jimenez RE, Folpe AL, Lapham RL, Ro JY, O'Shea PA, Weiss SW, Amin MB: **Primary Ewing's sarcoma/primitive neuroectodermal tumor of the kidney: a clinicopathologic and immunohistochemical analysis of 11 cases.** *Am J Surg Pathol* 2002, **26**:320-327.
7. Parham DM, Roloson GJ, Feely M, Green DM, Bridge JA, Beckwith JB: **Primary malignant neuroepithelial tumors of the kidney: a clinicopathologic analysis of 146 adult and pediatric cases from the National Wilms' Tumor Study Group Pathology Center.** *Am J Surg Pathol* 2001, **25**:133-146.
8. Thyavhally YB, Tongaonkar HB, Gupta S, Kurkure PA, Amare P, Muckaden MA, Desai SB: **Primitive neuroectodermal tumor of the kidney: a single institute series of 16 patients.** *Urology* 2008, **71**:292-296.
9. Chu WC, Reznikov B, Lee EY, Grant RM, Cheng FW, Babyn P: **Primitive neuroectodermal tumour (PNET) of the kidney: a rare renal tumour in adolescents with seemingly characteristic radiological features.** *Pediatr Radiol* 2008, **38**:1089-1094.
10. Ellinger J, Bastian PJ, Hauser S, Biermann K, Müller SC: **Primitive neuroectodermal tumor: rare, highly aggressive differential diagnosis in urologic malignancies.** *Urology* 2006, **68**:257-262.
11. Chan YF, Llewellyn H: **Intrarenal primitive neuroectodermal tumour.** *Br J Urol* 1994, **73**:326-327.
12. Marley EF, Liapis H, Humphrey PA, Nadler RB, Siegel CL, Zhu X, Brandt JM, Dehner LP: **Primitive neuroectodermal tumor of the kidney—another enigma: a pathologic, immunohistochemical, and molecular diagnostic study.** *Am J Surg Pathol* 1997, **21**:354-359.